RADIOGRAPHIC FEATURES OF CARDIOGENIC PULMONARY EDEMA IN THE CAT: 71 CASES

A Diana*, S Perfetti*, F Rigo#, M Baron Toaldo*, P Pey*, M Cipone*, H Poser#, C Guglielminl#

* Department of Veterinary Medical Sciences, University of Bologna, Italy.

Department of Animal Medicine, Production and Health, University of Padua, Italy.

Background

Cardiogenic pulmonary edema (CPE) is the most frequent cause of respiratory distress in cats due to left-sided congestive heart failure.

Thoracic radiography (RX) represents the reference standard diagnostic method in the confirmation and characterization of CPE.

The aims of this study are to describe the radiographic features of CPE in large group of cats with left-sided cardiac diseases and to ascertain if an association exists between the radiographic aspect of CPE and the underlying cardiac disease.

Material & Methods

- Cats with unequivocal diagnosis of acute onset CPE
- Echocardiographic (Echo) evidence of left-sided cardiac disease associated with left atrial enlargement (LAE)
- Two orthogonal radiographic projections of the thorax
- Rx and Echo exam performed within 24 hours of each other
- Review of Xray exams by the same experienced operator
- Subjective and objective evaluation:
  - cardiac silhouette (size and shape)
  - pulmonary vessels
  - pulmonary parenchyma (type, distribution and location of lesions)
- Student t test, Mann Whitney test, and two-proportion z-test to compare continuous and categorical variables between cats with HCM and RCM

Results

71 cats included: 46 HCM, 13 RCM, 6 NSCM, 4 DCM, 2 CHD

Table 1 and **Figure 1** show the results of cardiac silhouette evaluation
Subjective cardiomegaly was detected in 69 cats 79.6%)
LAE was subjectively diagnosed in 57 cats (80.3%) on lateral view
The valentine shape was observed in 38 cats (53.5%)

Table 2 shows the results of pulmonary vessels evaluation
Pulmonary artery abnormalities were detected in 52 cats (77.5%).

Table 3 and **Figure 2** show the results of pulmonary parenchyma evaluation
The interstitial pattern was the most represented (41 cats, 57.8%)
The multifocal distribution was the most represented (60 cats, 84.5%)
The ventro-caudal (42 cats, 65.6%) and ventro-cranial (39 cats 60.9%) location were the most frequently involved.

No significant difference was found for any tested variable between cats with HCM and RCM.

CARDIAC RADIOGRAPHIC FINDINGS

PARAMETER	All (n. = 71)	HCM (n. = 46)	RCM (n. = 13)	DCM (n. = 4)	NSCMP (n. = 6)	CHD (n. = 2)
Subjective cardiomegaly Absent/mild/moderate/severe (%)	2/12/36/21 (2.8/16.9/50.7/29.6)	0/11/21/14 (0/23.9/45.7/30.4)	0/1/9/3 (0/7.7/69.2/23.1)	0/0/4/0 (0/0/100/0)	2/0/2/2 (33.3/0/33.3/33.3)	0/0/0/2 (0/0/0/100)
Concave aspect caudal border (LV) Present/Absent/NE (%)	57/12/2 (80.3/16.9/2.8)	36/8/2 (78.3/17.4/4.3)	11/2/0 (84.6/15.4/0)	4/0/0 (100/0/0)	4/2/0 (66.7/33.3/0)	2/0/0 (100/0/0)
Notch on the caudal border (LV) Present/Absent/NE (%)	21/47/3 (29.6/66.2/4.2)	13/30/3 (28.3/65.2/6.5)	3/10/0 (23.1/76.9/0)	2/2/0 (50/50/0)	1/5/0 (16.7/83.3/0)	2/0/0 (100/0/0)
Presence of a mass on LA area (LV) Present/Absent/NE (%)	57/12/2 (80.3/16.9/2.8)	38/7/1 (82.6/15.2/2.2)	11/1/1 (84.6/7.7/7.7)	3/1/0 (75/25/0)	3/3/0 (50/50/0)	2/0/0 (100/0/0)
Valentine shape (VDV/DVV) Present/Absent/NE (%)	38/18/15 (53.5/25.4/21.1)	23/13/10 (50/28.3/21.7)	8/1/4 (61.5/7.7/30.8)	4/0/0 (100/0/0)	2/3/1 (33.3/50/16.7)	1/1/0 (50/50/0)
Double wall (VDV/DVV) Present/Absent/NE (%)	19/37/15 (26.8/52.1/21.1)	9/26/11 (21.3/55.3/23.4)	4/5/4 (30.8/38.4/30.8)	4/0/0 (100/0/0)	1/5/0 (16.7/83.3/0)	1/1/0 (50/50/0)
CLA - LV mean ± SD	5.4 ± 0.5 (n. = 67)	5.4 ± 0.4 (n. = 44)	5.4 ± 0.3 (n. = 12)	5.5 ± 0.4	5.4 ± 0.5 (n. = 5)	6.6 ± 1.6
CSA - LV mean ± SD	3.9 ± 0.5 (n. = 62)	3.8 ± 0.4 (n. = 40)	3.9 ± 0.3 (n. = 11)	3.9 ± 0.3	3.9 ± 1 (n. = 5)	5.2 ± 1.6
VHS - LV median (range)	9.2 (7.5-14) (n. = 62)	9.0 (8.1-10.8) (n. = 40)	9.5 (8.6-10.1) (n. = 11)	9.25 (8.5-10.2)	9.4 (7.5-11) (n. = 5)	11.7 (9.4-14)
LA - VHS median (range)	1.3 (0.8-3.1) (n. = 64)	1.3 (0.8-2.0) (n. = 42)	1.45 (1.0-2.3) (n. = 12)	1.55 (1-1.7)	1.5 (1.2-1.7) (n. = 5)	2.2 (1.3-3.1)

TABLE 1. Subjective and objective radiographic findings regarding cardiac abnormalities in 71 cats with acute left-sided CHF. Abbreviations: NE, Not Evaluable; LV, Lateral view; VDV, Ventro-Dorsal View; DVV, Dorso-Ventral View; CLA, Cardiac Long Axis; CSA, Cardiac Short Axis; VHS, Vertebral Heart Score. LA-VHS, left atrial VHS; n., number of cats; HCM, Hypertrophic Cardiomyopathy; RCM, Restrictive Cardiomyopathy; DCM, Dilated Cardiomyopathy; NSCMP, Non-specific Cardiomyopathy; CHD, Congenital Heart Disease.

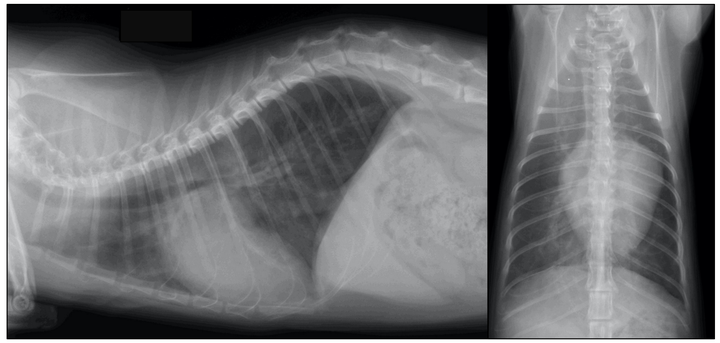

Figure 1. Nine-month-old DSH cat. On the right lateral projection(A) concave aspect of the caudal border of the cardiac silhouette and bulging of the left atrial area is noticed. On ventro-dorsal projection (B) Valentine shape of the cardiac silhouette is evident.

PULMONARY VESSELS RADIOGRAPHIC FINDINGS

PARAMETER		All (n. = 71)	HCM (n. = 46)	RCM (n. = 13)	DCM (n. = 4)	NSCMP (n. = 6)	CHD (n. = 2)
PA abnormality Present/Absent/NE (%)		55/14/2 (77.5/19.7/2.8)	37/8/1 (80.4/17.4/2.2)	8/4/1 (61.5/30.8/7.7)	3/1/0 (75/25/0)	5/1/0 (83.3/16.7/0)	2/0/0 (100/0/0)
If Present	Dilatation (%)	52 (94.5) (n. = 55)	35 (94.6) (n. = 37)	8 (100) (n. = 8)	2 (66.7) (n. = 3)	5 (100) (n. = 5)	2 (100)
	Tortuosity (%)	3 (5.4) (n. = 55)	2 (5.4) (n. = 37)	0 (0) (n. = 8)	1 (33.3) (n. = 3)	0 (0) (n. = 5)	0 (0)
	Pruning (%)	0 (0) (n. = 55)	0 (0) (n. = 37)	0 (0) (n. = 8)	0 (0) (n. = 3)	0 (0) (n. = 5)	0 (0)
Lung lobe/lobes involved RCau/LCau/RCr/LCr (%)		50/50/22/24 (90.9/90.9/40/43.6) (n. = 55)	35/33/13/14 (94.6/89.2/35.1/37.8) (n. = 37)	8/8/4/4 (100/100/50/50) (n. = 8)	2/2/2/2 (50/50/50/50) (n. = 1)	4/5/2/3 (66.7/83.3/33.3/50)	1/2/1/1 (50/100/50/50)
Dilatation Cranial vessels Present/Absent/NE (%)		10/53/8 (14/74.7/11.3)	6/34/6 (13/74/13)	2/10/1 (15.4/76.9/7.7)	0/4/0 (0/100/0)	1/4/1 (16.7/66.6/16.7)	1/1/0 (50/50/0)
Dilatation Caudal vessels Present/Absent/NE (%)		50/14/7 (70.4/19.7/9.9)	34/8/4 (73.9/17.4/8.7)	7/3/3 (53.8/23.1/23.1)	2/2/0 (50/50/0)	5/1/0 (83.3/16.7/0)	2/0/0 (100/0/0)
Ratio PA/PV on LV 1:1/A>V/V>A/NE (%)		51/3/3/14 (71.8/4.3/4.2/19.7)	33/2/2/9 (71.8/4.3/4.3/19.6)	7/1/1/4 (53.8/7.7/7.7/30.8)	4/0/0/0 (100/0/0/0)	5/0/0/1 (83.3/0/16.7)	2/0/0 (100/0/0)
Ratio PA/PV on DVV/VDV 1:1/A>V/V>A/NE (%)		39/16/1/15 (55/22.5/1.4/21.1)	24/10/1/11 (52.2/21.7/2.2/23.9)	8/3/0/2 (61.5/23.1/0/15.4)	2/0/0/2 (50/0/0/50)	4/2/0/0 (66.7/33.3/0/0)	1/1/0/0 (50/50/0/0)

TABLE 2. Subjective and objective radiographic findings regarding pulmonary vessels abnormalities in 71 cats with cardiogenic pulmonary edema. Abbreviations: n., number of cats; PA, Pulmonary Artery; RCau, Right Caudal; LCau, Left Caudal; RCr, Right Cranial; LCr, Left Cranial; NE, Not Evaluable; PA/PV, Pulmonary Artery/Pulmonary Vein; A/V, Artery/Vein; LV, Lateral view; DVV, Dorso-Ventral view; VDV, Ventro-Dorsal view; A>V, Artery > Vein; V >A, Vein >Artery; n., number of cats; HCM, Hypertrophic Cardiomyopathy; RCM, Restrictive Cardiomyopathy; DCM, Dilated Cardiomyopathy; NSCMP, Non-specific Cardiomyopathy; CHD, Congenital Heart Disease.

LUNG PARENCHYMA RADIOGRAPHIC FINDINGS

PARAMETER		All (n. = 71)	HCM (n. = 46)	RCM (n = 13)	DCM (n. = 4)	NSCMP (n. = 6)	CHD (n. = 2)
Pulmonary Pattern Interstitial/Alveolar/Mixed/NE (%)		41/1/27/2 (57.8/1.4/38/2.8)	25/1/18/2 (54.3/2.2/39.1/4.4)	8/0/5/0 (61.5/0/38.5/0)	3/0/1/0 (75/0/25/0)	4/0/2/0 (66.7/0/33.3/0)	1/0/1/0 (50/0/50/0)
Distribution Focal/Multifocal/Diffuse/NE (%)		3/60/6/2 (4.2/84.5/8.5/2.8)	1/41/3/1 (2.2/89.1/6.5/2.2)	1/9/2/1 (7.7/69.2/15.4/7.7)	1/2/1/0 (25/50/25/0)	0/6/0/0 (0/100/0/0)	0/2/0/0 (0/100/0/0)
Symmetrical or Asymmetrical (if multifocal)	Symmetrical/RA/LA (%)	45/13/2 (75/21.7/3.3)	32/8/1 (78/19.5/2.5)	5/4/0 (55.6/44.4/0)	2/0/0 (100/0/0)	5/1/0 (83.3/16.7/0)	1/1/0 (50/50/0)
If focal or multifocal	Dorso-Cranial%)	0 (0) (n. = 64)	0 (0) (n. = 42)	0 (0) (n. = 11)	0(0) (n. = 3)	0(0) (n. = 6)	0(0) (n. = 2)
	Dorso-Caudal(%)	22 (34.4) (n. = 64)	13 (31) (n. = 42)	4 (36.3) (n. = 11)	2 (66.7) (n. = 3)	2 (33.3) (n. = 6)	1 (100) (n. = 2)
	Ventro-Cranial(%)	39 (60.9) (n. = 64)	29 (69) (n. = 42)	4 (36.3) (n. = 11)	0 (0)	4 (66.7) (n. = 6)	2 (100) (n. = 2)
	Ventro-Caudal (%)	42 (65.6) (n. = 64)	31 (73.8) (n. = 42)	6 (54.5) (n. = 11)	0 (0) (n. = 3)	3 (50) (n. = 6)	2 (100) (n. = 2)
	Central (Hilar) (%)	16 (25) (n. = 64)	7 (16.7) (n. = 42)	5 (45.4) (n. = 11)	2 (66.7) (n. = 3)	1(16.7) (n. = 6)	1(50) (n. = 2)
Bronchial Pattern Present/Absent/NE (%)		40/30/1 (56.3/42.3/1.4)	27/19/0 (58.7/41.3/0)	5/8/0 (38.5/61.5/0)	3/1/0 (75/25/0)	5/0/1 (83.3/0/16.7)	0/2/0 (0/100/0)

TABLE 2. Radiographic findings of lung parenchymal abnormalities in 71 cats with CPE. Abbreviations as in Table 1.

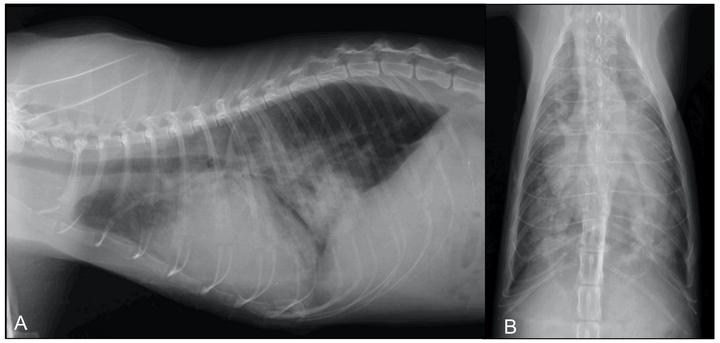

Figure 2. Thoracic radiographs of a 10 years-old DSH cat. On the right lateral projection(A) a cranio-ventral and caudo-ventral interstitial-alveolar pattern is noticed. On dorso-ventral projection (B) the symmetric distribution of interstitial-alveolar pattern is more pronounced.

Conclusion

Most of cats with CPE have moderate cardiomegaly and LAE, best noticeable in lateral view.

The interstitial pulmonary pattern, with prevalent multifocal distribution and mainly located in caudo-ventral and cranio-ventral position is the most prevalent radiographic presentation.

The underlying left-sided cardiac disease does not seem to have an influence on the above radiographic features.

EVDI ONLINE CONGRESS 23-24 SEPTEMBER 2021