Small intestinal entrapment by a ductus deferens in a dog

Aurélie Bruwier, Jean Bassanino, Dimitri Leperlier, Laure Gatel, Anne-Sophie Bedu.
CHV Pommery

Introduction:

- 3-year-old intact male WHWT, unremarkable medical history.
- Clinical signs: lethargy, acute abdomen, anorexia, and vomiting.
- Physical examination: right inguinal cryptorchidism.

Methods:

- Biological, diagnostic imaging (X-RAY, US and CT) and laparotomy.

Results:

- Biochemistry and blood count : within normal limits.
- **X-RAY** (figure 1) and **US** (figure 2): a focal, distended small intestinal segment with an edematous wall, marked focal steatitis, and mesenteric congestion. A vascular impairment was suspected.
- Abdominocentesis: modified transudate with red blood cells and some neutrophils, absence of intracellular bacteria.

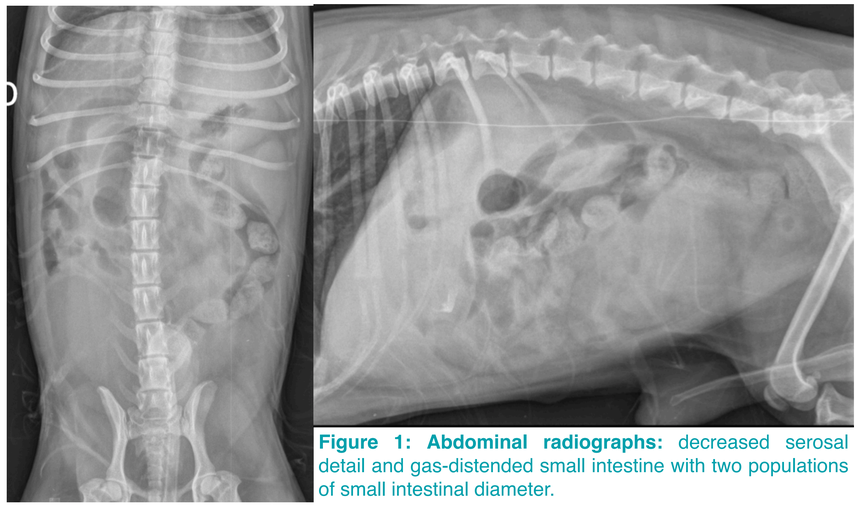

Figure 1: Abdominal radiographs: decreased serosal detail and gas-distended small intestine with two populations of small intestinal diameter.

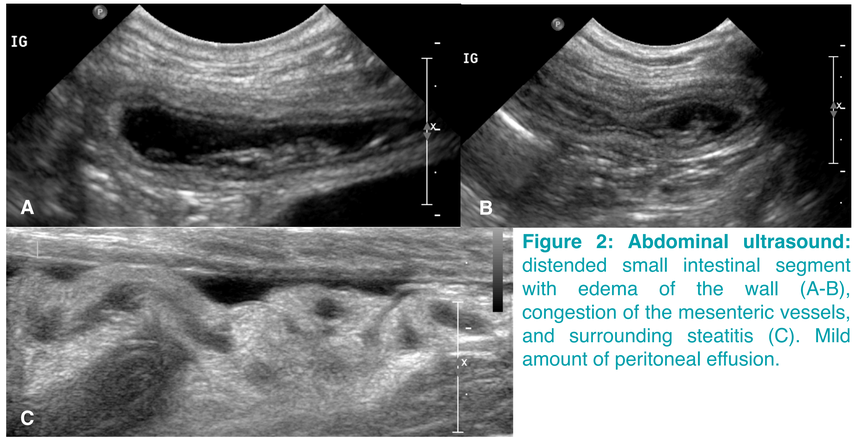

Figure 2: Abdominal ultrasound: distended small intestinal segment with edema of the wall (A-B), congestion of the mesenteric vessels, and surrounding steatitis (C). Mild amount of peritoneal effusion.

- **Contrast-enhanced CT** (figure 3):

- Focal increased attenuation of the mesenteric fat and mild peritoneal effusion
- Moderate segmental bowel dilatation with decreased enhancement of the small intestine wall

Figure 3: Computed tomography: sagittal (A-C) and dorsal (D-F) post-contrast images in soft tissue window (A-F) and MIP reconstruction (F). The arrows delineate the mildly to moderately thickened left ductus deferens which strangles the small intestinal loops. The blue line underlines the course of the left ductus deferens (F). (* dilated poor contrast enhancing loops, ** left epididymis and testis)

- Entrapment of the distal jejunum and part of the ileum through the elongated left ductus deferens in the left caudal abdomen

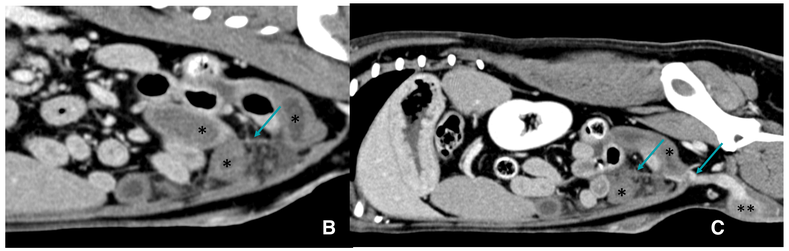

- Marked congestion of the mesenteric vasculature of the entrapped small intestinal segment
- Mild to moderate thickening of the left ductus deferens
- Cranial displacement of the testis and the epididymis in the left inguinal region.

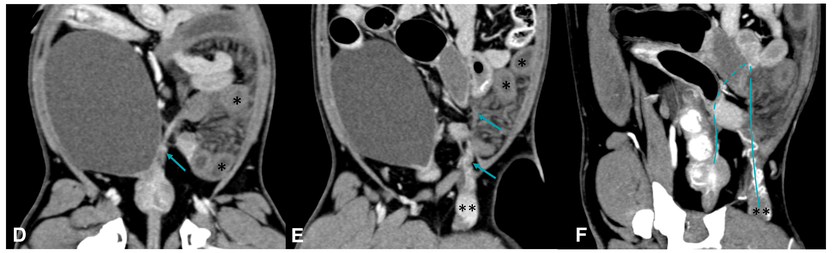

- Small intestinal entrapment by the left ductus deferens and secondary bowel ischemia

- **Surgery** (figure 4): **Small intestinal entrapment by the left ductus deferens was confirmed.** An enterectomy was performed.
- The dog recovered uneventfully.
- One year after the surgery the dog was clinically normal.

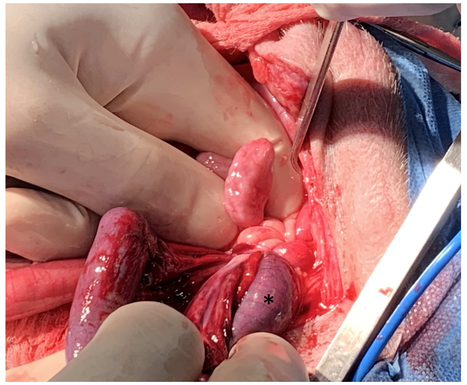

Figure 4: Surgery: laparotomy confirmed a jejunoileal entrapment by the left ductus deferens, segmental bowel ischemia (*), and mesenteric congestion.

Discussion:

- Intestinal entrapment is a rare condition in dogs and has been described secondary to postoperative adhesions or duodenocolic ligament rupture.
- Entrapment of a small intestine segment through the ductus deferens has been described in castrated steers and in horses.
- In human medicine, the most common cause of small bowel obstruction is postoperative adhesion formation. A case of small bowel obstruction caused by a remnant of the vas deferens has been described in a young adult after an orchidectomy.
- **To the author knowledge, this is the first description of primary small intestinal entrapment by a ductus deferens without any previous surgery in a dog.**

References:

- Hassinger KA. Intestinal Entrapment and Strangulation Caused by Rupture of the Duodenocolic Ligament in Four Dogs. *Vet Surg* 1997; 26: 275-280.
- Swift I. Ultrasonographic feature of intestinal entrapment in dogs. *Vet Radiol Ultrasound* 2009; 50 (2): 205-207.
- Di Cicco MF. Segmental jejunal entrapment, volvulus, and strangulation secondary to intra-abdominal adhesions in a dog. *J Am Anim Hosp Assoc* 2011; 47 (3): 31-35.
- Wolfr DF, et all. Incarceration of a section of small intestine by remnants of the ductus deferens in steers. *J Am Vet Med Assoc* 1987; 191 (12): 1597-1598.
- Davis J, et all. Small bowel obstruction caused by vas deferens: a first documented report. *BMJ Case Rep* 2018.

Contact: Aurélie Bruwier, ECVDI resident
a.bruwier.vet@gmail.com
Diagnostic Imaging Unit, CHV Pommery,
226 Boulevard Pommery, Reims, France