THE UNIVERSITY of EDINBURGH
The Royal (Dick) School of Veterinary Studies

EVDI ANNUAL CONGRESS

MAGNETIC RESONANCE IMAGING AND HISTOPATHOLOGICAL FEATURES OF A BUTTERFLY GLIOBLASTOMA IN A TWO-YEAR OLD DOG

YL Tan[1], M Kelley[1,2], T Schwarz[1], J Del-Pozo[1], A Suñol[1,3]

1. 1Royal (Dick) School of Veterinary Studies, University of Edinburgh, Roslin EH25 9RG, UK
2. Medvet Dallas, 11333 N. Central Exwy Dallas, TX75243
3. Anicura Ars Veterinaria Hospital Veterinari, Carrer dels Cavallers, 37, 08034 Barcelona, Spain

INTRODUCTION

This report describes the clinical, MRI and post-mortem findings of a unique, rarely reported presentation of a butterfly glioblastoma in a young dog.

METHODS

A two-year-old female neutered Cockapoo was presented with lethargy and abnormal neurological episodes including obtunded mentation and behaviour, as well as generalised epileptic seizures. A brain MRI was performed using a 1.5T scanner, which included T2-weighted, T1-weighted pre- and post-contrast, T2 FLAIR, T2*GE and DWI sequences. The patient was euthanised, and post-mortem examination and histopathology were performed.

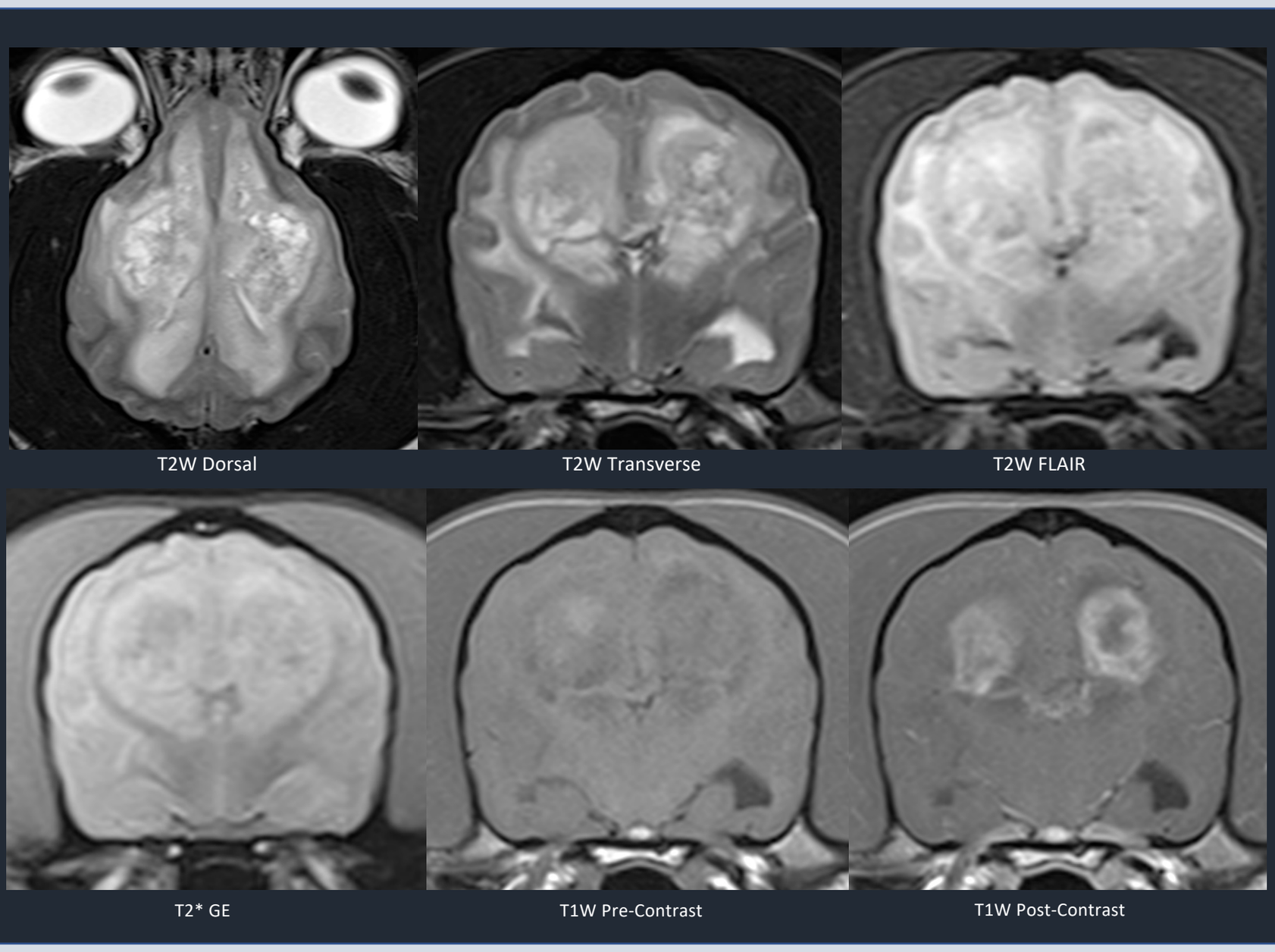

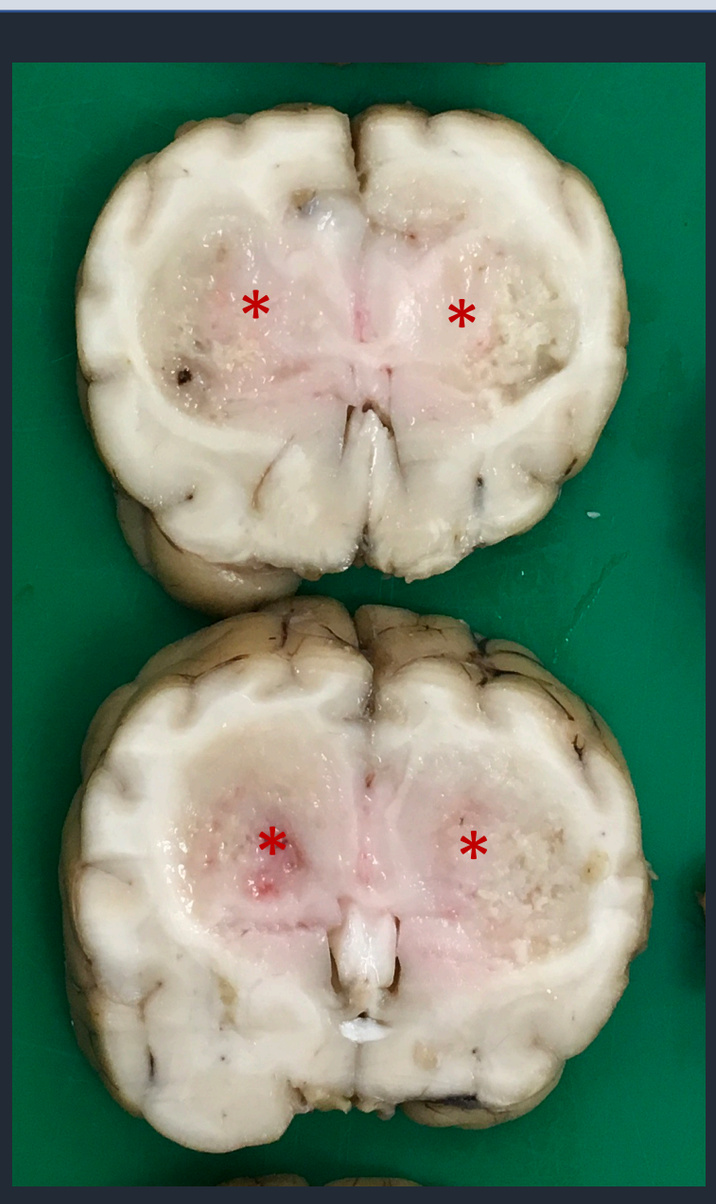

RESULTS

The MRI showed a bi-hemispheric, intra-axial, contrast-enhancing mass lesion within the forebrain that was extending across the corpus callosum and was mimicking an intraventricular bilateral symmetrical lesion. Post-mortem examination demonstrated a symmetrically effacing, infiltrative neoplasm that was replacing approximately 75% of the neuropil at the centre of the forebrain and midbrain. Histopathological assessment of this lesion was consistent with a high-grade astrocytoma such as glioblastoma multiforme. Given the bi-hemispheric, wing-like appearance on MRI and histopathological features, this lesion has been further classified as a butterfly glioblastoma.

DISCUSSION

The MRI and histopathological findings of this case are consistent with a butterfly glioblastoma, which is a rare condition in human and veterinary medicine, and the first case reported in a young dog. In human medicine, butterfly glioblastomas describe high-grade astrocytomas that extend across the midline via white matter commissures. Butterfly glioblastoma, although rare, should be considered in bilateral symmetrical lesions that could mimic an intraventricular neoplasia.

Corresponding author: yilin.tan@ed.ac.uk