COMPUTED TOMOGRAPHY APPEARANCE OF THE NORMAL THYMUS IN DOGS: A DESCRIPTIVE AND ANATOMICAL STUDY

A. Compagnino[1], C. Puccinelli[1], M. Mattolini[1,2], F. Rossi[2], S. Citi[1]

[1]*Department of Veterinary Sciences, University of Pisa, San Piero a Grado (PI), Italy.*
[2]*Clinica Veterinaria dell'Orologio, Sasso Marconi (BO), Italy.*

Introduction

The thymus is a lymphatic organ located in the cranial mediastinum, presenting maximum development before sexual maturity, followed by an involution phase where the glandular tissue is replaced by fat. Few information is available about CT appearance and regression of the normal thymus in dogs.[1,2] **This retrospective study aimed to describe the CT appearance and involution rate of the normal thymus in dogs between 1 and 24 months of age.**

Material and Methods

Dogs under 2 years of age with a normal CT scan of the thorax performed were included and grouped in 4 categories (0-6, 6-12, 12-18 and 18-24 months). Post-contrast CT images were analyzed using two approaches: 1. **qualitative evaluation** of the thymus shape, location, anatomical relationships and grade of involution/replacement of the thymic tissue with fat 2. **quantitative assessment** including the ratio between the fourth thoracic vertebra body volume and the volume of the thymus (T4/Thymus) and gland attenuation. Correlation between age, grade of involution, ratio T4/Thymus, and attenuation was assessed by the Spearman test.

Results

Forty-three dogs, 21 males and 22 females, were included. Age distribution was similar in the 4 groups. In most cases, a cranial part with rounded margins and a thinner triangular caudal part were distinguishable. Two lobes could be distinguishable in dogs within 12 months of age.

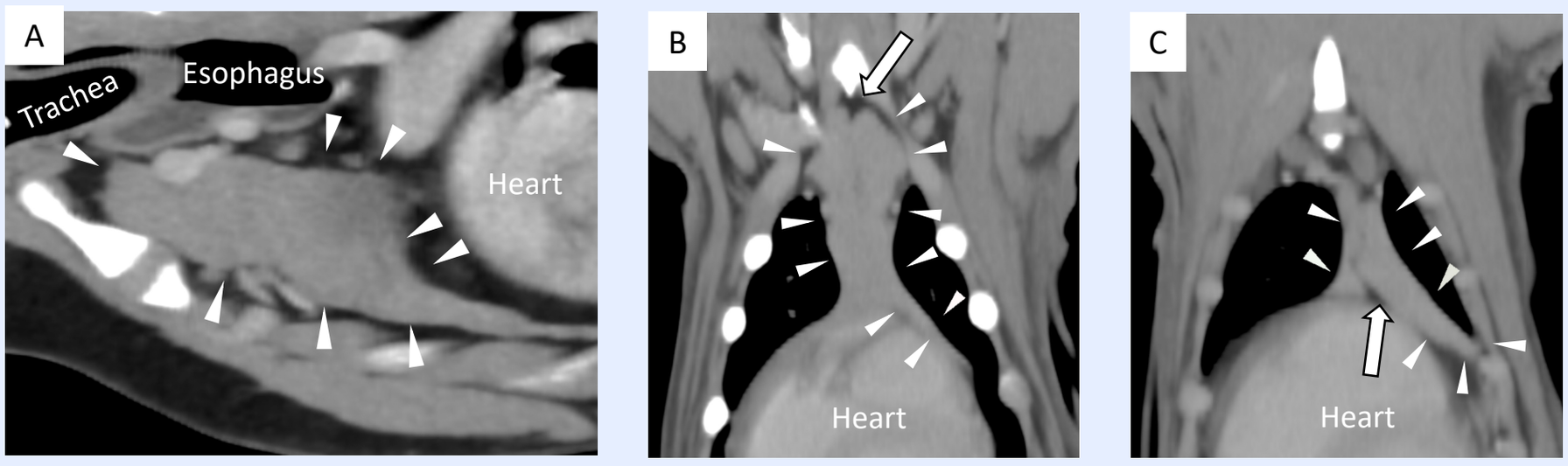

(A) *Female dog of 5 months.* Oblique lateral view of the thymus. Note the vaguely triangular shape of the thymus (arrowheads), the dorsal trachea and esophagus, the caudal heart and the ventral first sternebras; **(B)** Dorsal view of the dorsal part of the thymus (arrowheads). Note the bilobed cranial part (arrow) and caudally the thin apex of the left lobe; **(C)** Dorsal view of the ventral part of thymus (arrowheads). Note a hypodense septum (arrow) dividing the two thymic lobes.

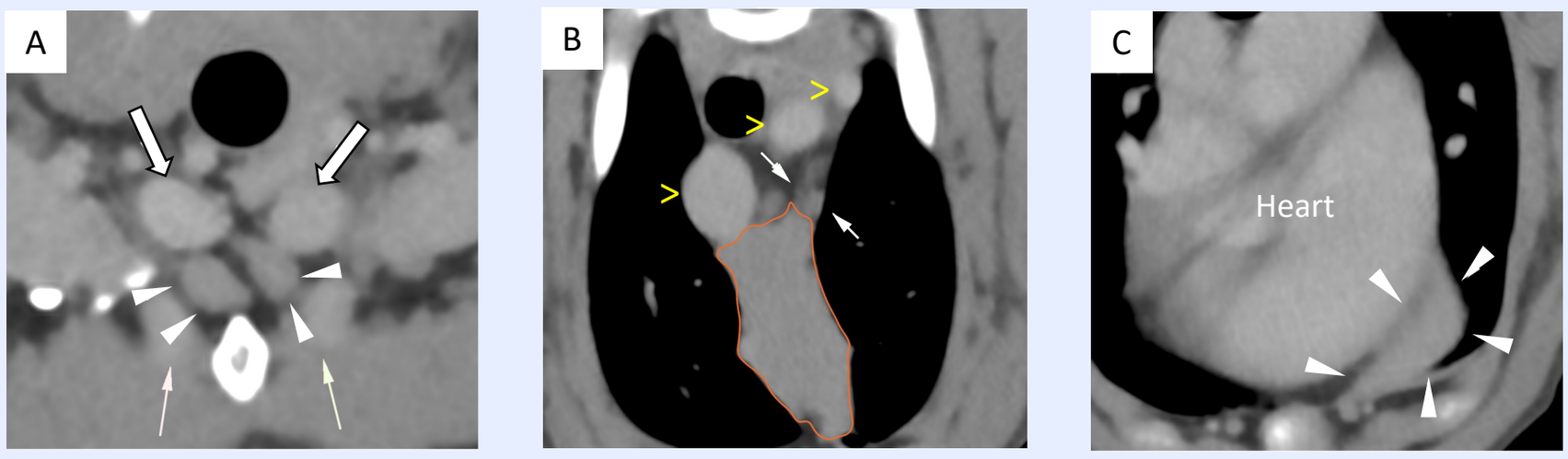

Female dog of 3 months. Transverse view of the cranial **(A)**, central **(B)** and caudal **(C)** portions of the thymus (arrowheads). **(A)** Note the coffee beans shape of thymus lobes and the anatomical limits given by the first sternebra, the sternohyoid and sternothyroid muscles (small arrows), and the brachiocephalic venous trunks (large arrows); **(B)** Note the anatomical relationships of the thymus (orange line) with cranial vena cava, brachiocephalic arterial trunk and left subclavian artery, going from right to left (yellow arrowheads), and the dorsal lymph node station (white arrows); **(C)** Note the caudal part of the thymus located in the left hemithorax (arrowheads).

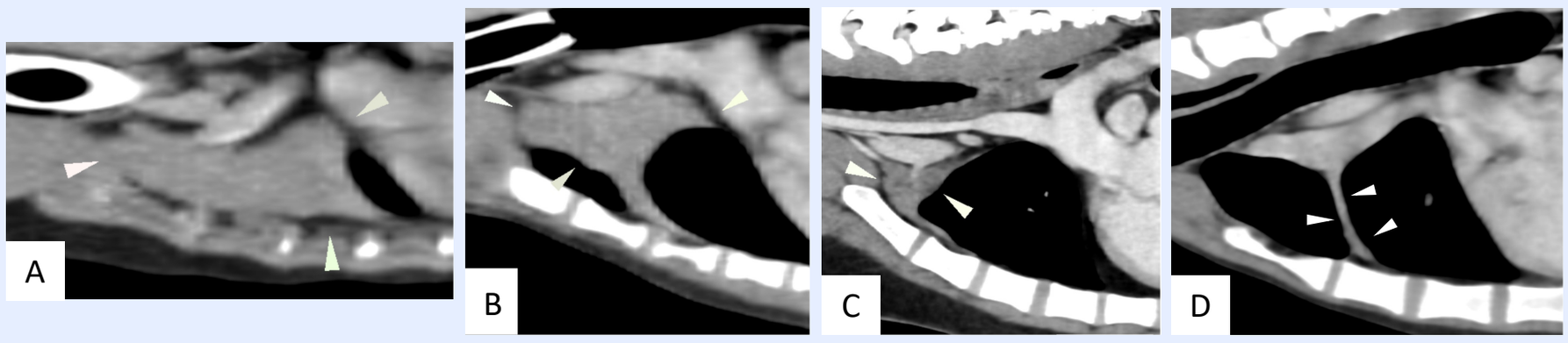

Longitudinal views of thymus involution grades (arrowheads). **(A)** *Male dog of 4 months.* Grade A; **(B)** *Male dog of 8 months.* Grade B; **(C)** *Male dog of 19 months.* Grade C; **(D)** *Female dog of 23 months.* Grade D.

Based on replacement of thymic tissue with adipose tissue, 4 grades of involution were described: from Grade 1 (no involution) to Grade 4 (maximum involution). The grade of involution and the ratio T4/thymus increased with the age of patients in the 4 groups of age, and the attenuation decreased ($p<0.0001$).

Conclusions

This is the first study providing information about the CT anatomy and normal involution of the canine thymus during growth. These data will be useful for the CT interpretation of the cranial mediastinum in young dogs.

References

1. Wisner E, Zwingenberger A. *Atlas of small animal CT and MRI*. Wiley Blackwell, 2015
2. Schwar T, Saunders J. *Veterinary Computed Tomography*. Wiley Blackwell, 2011