Accuracy of Computed Tomography attenuation values in the characterization of ascites in dogs – a preliminary study

Fiegna S[1], Zoia A[2], Costa A[1], Mazzei A[2], Cordella A[3], Bertolini G[1]

[1] Diagnostic and Interventional Radiology Division, San Marco Veterinary Clinic and Laboratory;
[2] Internal Medicine Division, San Marco Veterinary Clinic and Laboratory;
[3] Department of Medical Imaging, Faculty of Veterinary Medicine, Ghent University.

PURPOSE

To assess the utility of computed tomography (CT) in characterizing canine ascites on the basis of the attenuation values.

METHODS

Study design: 10-year single-centre cross-sectional study.
Patients: 498 ascitic dogs underwent CT examination of the abdomen with a 2nd or 3rd generation Dual Source CT scanner (Siemens Somatom Definition Flash and Force).
Eligibility criteria:

- abdominal effusion (moderate to severe);
- CT and diagnostic abdominocentesis performed within 48 hours of each other;
- complete hematobiochemical profile;
- final diagnosis for the ascites formation. According to the patho-physiology of its formation, ascites was categorized into: exudate, transudate, hemoabdomen, and uroabdomen.

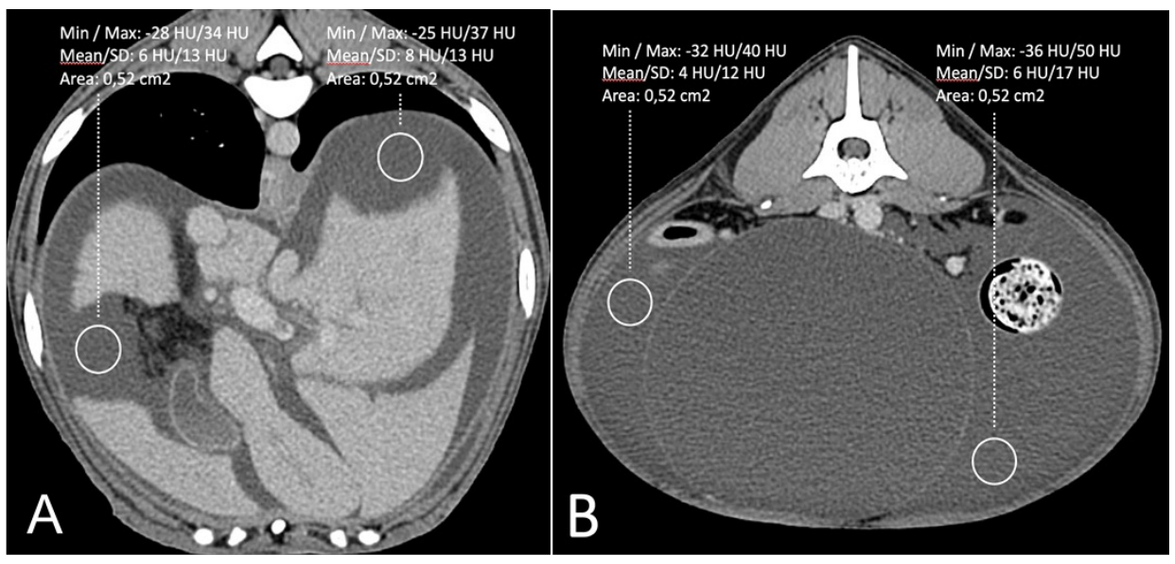

Figure 1A, B. Description in the text.

A total of 4 round, same size, regions of interest (ROIs) were drawn on the fluid identified in the cranial and caudal CT sections of the abdomen, in dorsal and ventral position, and the CT numbers were recorded (Figure 1A, B). For each ROI were registered: mean, minimum, maximum attenuation values and standard deviation.
Mean of the four ROI mean values (mean of the means) were compared between types of ascites (Kruskal-Wallis, pairwise comparison Bonferroni-adjusted). Cut-off values for discriminating type of ascites were determined (ROC-curve analysis). Significance was set to $\alpha = 0.05$.

RESULTS

88 dogs met the inclusion criteria: exudate (*n*=26), transudate (*n*=25), haemoabdomen (*n*=25), and uroabdomen (*n*=12). Median (IQR) of the "mean of the means" attenuation values are reported in Table 1 and displayed in Figure 2.
Post-hoc analysis showed significant differences between all groups with the exception of exudate and uroabdomen (Table 2).
The area under the curve ([AUC], i.e., accuracy) of the attenuation values to discriminate haemoabdomen from all other types of ascites was 95.5% (Youden Index ≥ 18.5 HU; Figure 3).
The AUC of the attenuation values to discriminate transudate from other types of ascites was 95.1% (Youden Index < 11 HU; Figure 4).
Attenuation values between 11–18.5 HU were less informative on the nature of the ascites.

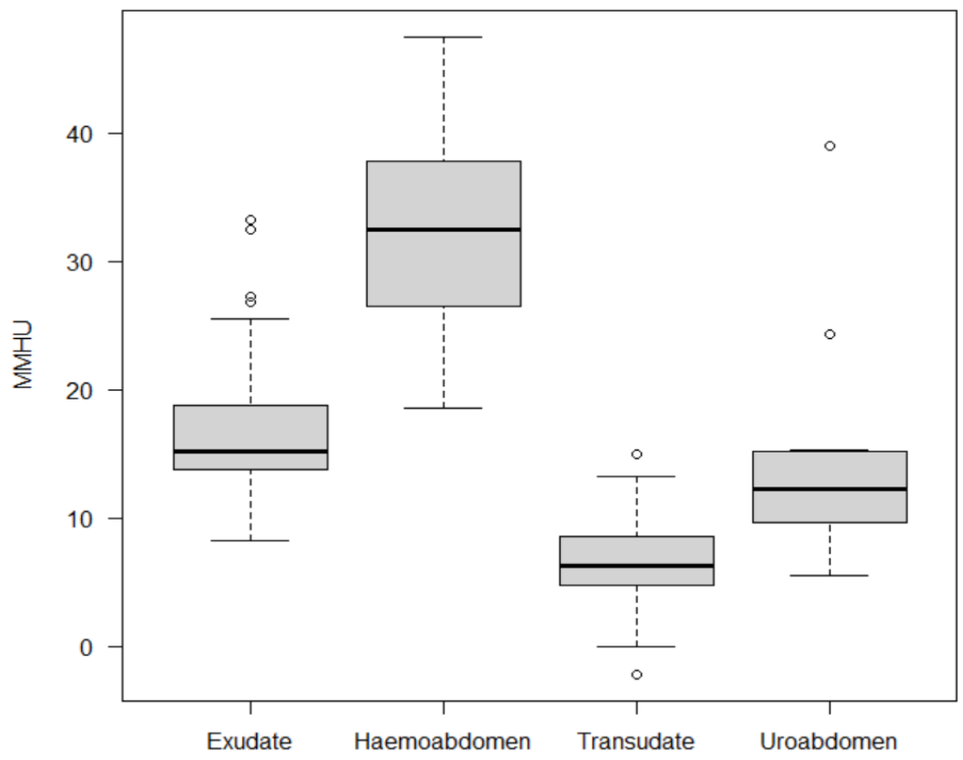

Fig. 2 Median attenuation values (MMHU) within different types of abdominal effusions.

Tab. 1 E: exudate; H: haemoabdomen; T: transudate; U: uroabdomen.

E Median (IQR) (HU)	H Median (IQR) (HU)	T Median (IQR) (HU)	U Median (IQR) (HU)	Kruskal-Wallis	Pairwise comparison (P-value)
15.12 (13.87-18.31)	32.50 (26.59-37.75)	6.25 (4.75-8.50)	12.25 (10.31-15.06)	P<0.001	E>T (P<0.001) E<H (P<0.001) T<H (P<0.001) H>U (P<0.001) T<U (P=0.007) E>U (P=0.369)

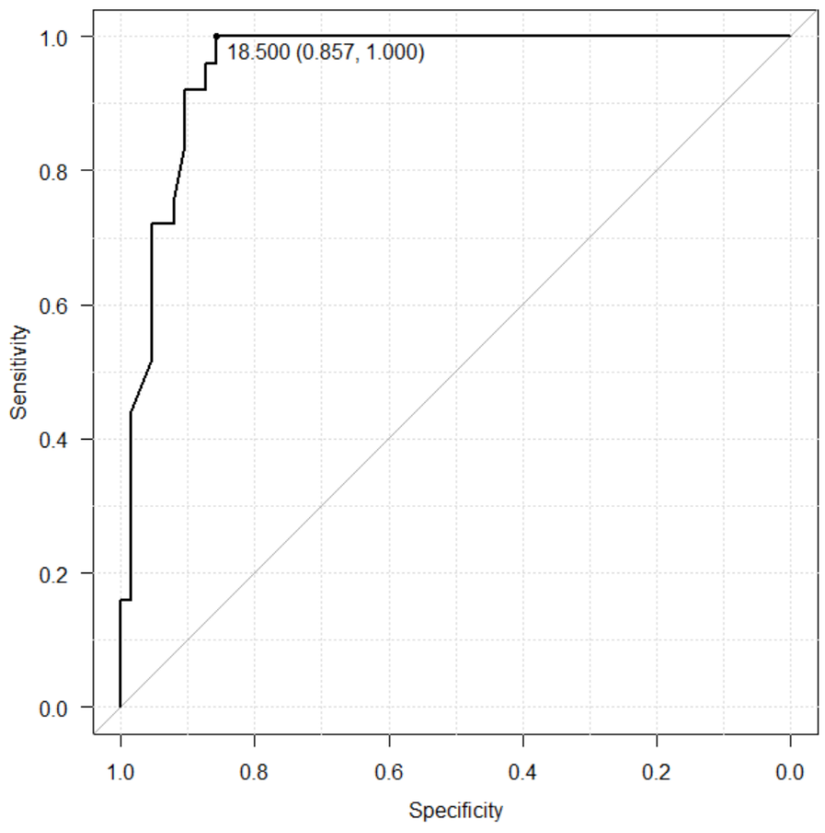

Fig. 3 ROC-curve: **haemoabdomen** versus other types of ascites. *P* < 0.001; 95%CI=91.5 – 99.4%; **Youden Index ≥ 18.5 HU**, Sensitivity= 100%, Specificity= 85.7%).

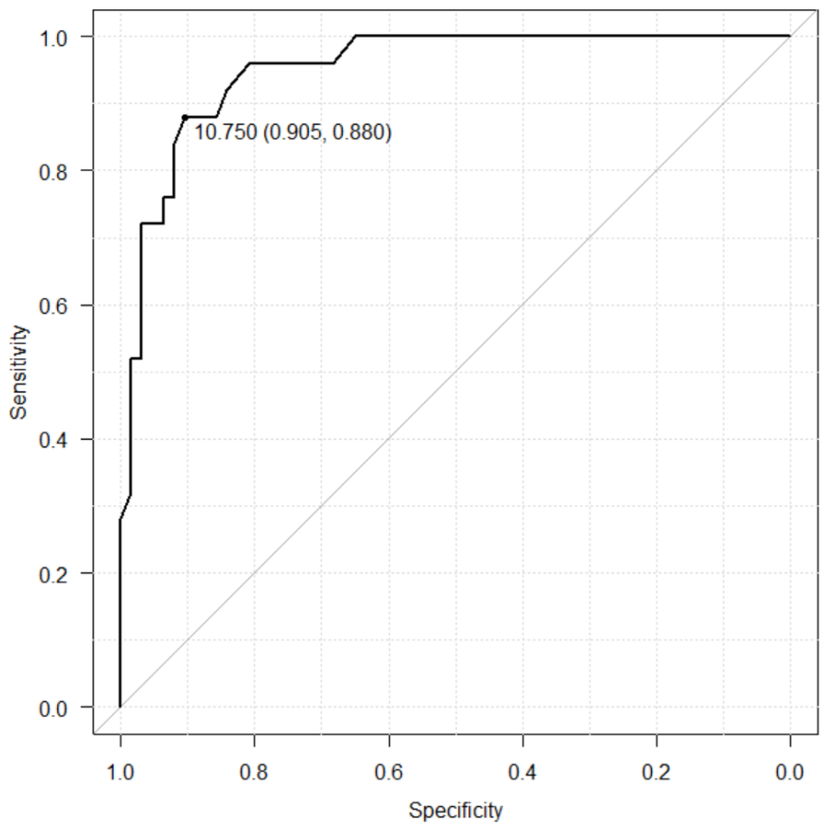

Fig. 4 ROC-curve: **transudate** versus other types of ascites. *P* < 0.001; 95%CI=91.0 – 99.3%; **Youden Index < 11 HU**, Sensitivity= 90.5%, Specificity= 88%.

CONCLUSION

CT attenuation values resulted excellent in discriminating **haemoabdomen** and **transudate** from all other types of ascites.