# 7T MRI of the equine cadaver foot:

## preliminary results of potential sequences evaluating morphology

M Magnusson[1,2], S Kaessmeyer[2], B Jung[3,4], D Schweizer[1,4], E Van der Vekens[1,4]

[1] Vetsuisse Faculty, Division of Clinical Radiology, University of Bern, Switzerland, [2] Vetsuisse Faculty, Division of Veterinary Anatomy, University of Bern, Switzerland, [3] Institute of Diagnostic, Interventional and Paediatric Radiology, University Hospital Bern, Bern, Switzerland; [4] Translational Imaging Center Bern

**Background:** 7T MRI of 1 $\mathrm{cm}^3$ equine hoof wall cubes was published in 2006[a], but only recently developped clinical UHF MRIs allow scans of the entire equine distal limb. While multiple protocols for low and high field MRI of the equine foot exist, specific UHF MRI sequences have been reported to provide better results in human musculoskeletal imaging.

**Aims:** The aims of this pilot study were to evaluate the (1) usibility and (2) quality of 8 sequences reported in ultra-high-field (UHF) human musculoskeletal MRI[b,c,d] for morphological examination of the distal equine cadaver limb.

**Method:** Sagittal 2D (T1wSE , T2wSE, PDw fs and non-fs) and 3D (T1w-MP-RAGE, CISS, DESS, FLASH and SWI), dorsal and transverse T1wSE images were acquired with a 7T Siemens MAGNETOM in one frozen-thawed and one fresh, radiographically normal equine cadaver limb. Sequences were assessed for subjective image quality and visualization of anatomical structures and compared to corresponding anatomical cross-sections.

**Results:** Results are shown in Figure 1 and summarized in Tables A and B.

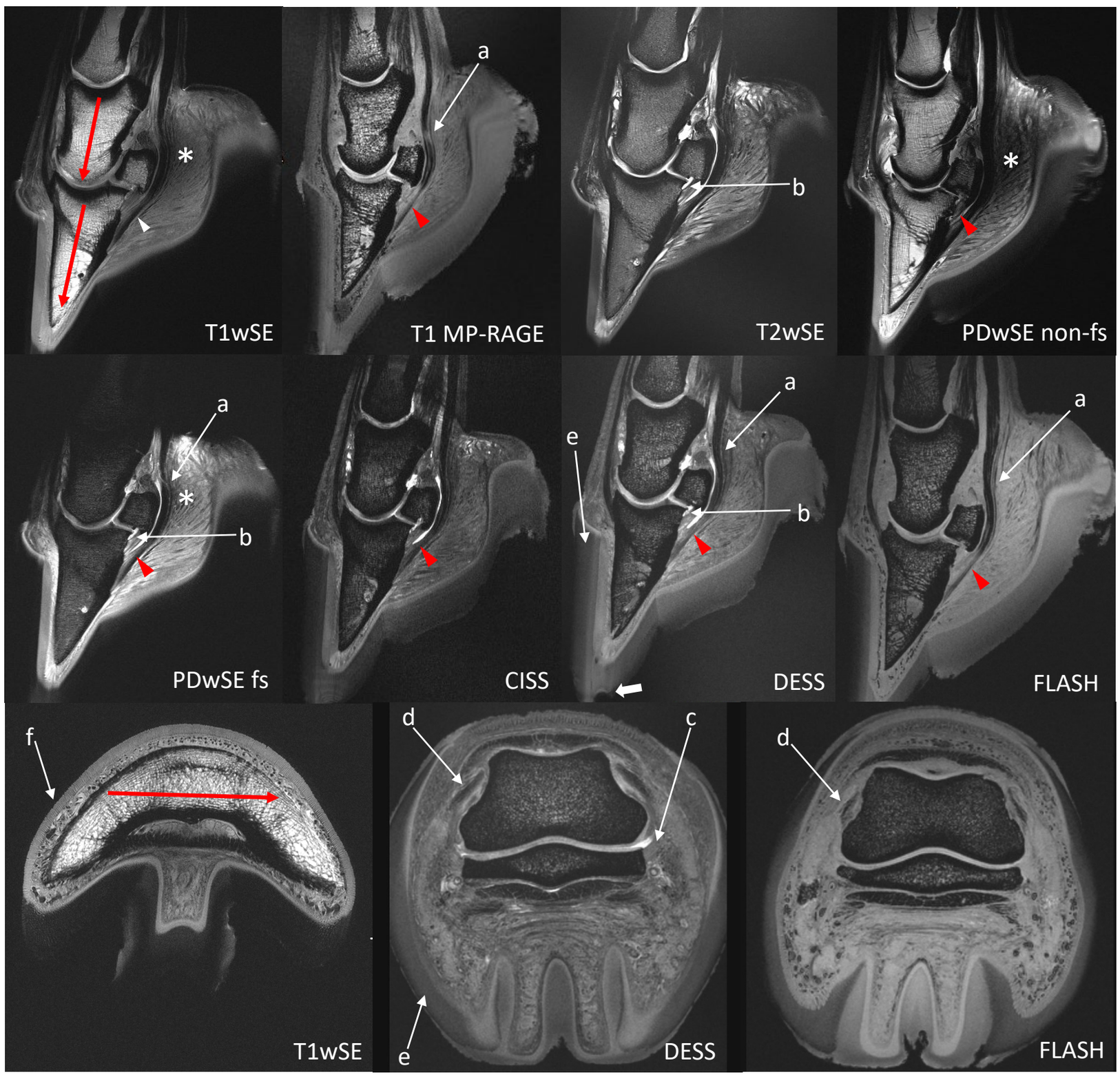


**Figure 1.** 7T MRI images of the equine distal limb of the different sequences acquired in sagittal and transverse plane. Transverse T1wSE image is located at the level of the distal sesamoidean impar ligament (DSIL) insertion and transverse DESS and FLASH images are located at the level of the head of the middle phalanx.

Note the distal digital annular ligament (DDAL) (a), synovial fossae of the distal interphalangeal joint (DIPJ) (b), chondrosesamoidean ligament (ChSL) (c), collateral ligaments of the DIPJ (d). Stratum medium (e) and lamellar zone (f).

Note the massive chemical shift artifact on non-fat-suppressed images (red arrow), magic angle artifact (arrowheads) B1 inhomogeneity on T1ySE, PDwSE non-fs (asterisk), and small susceptibility artifact on DESS (fat arrow).

**Table A.** Artifacts and location

| Artifacts and location | Sequences |
|---|---|
| Chemical shift artifacts:<br>- bone marrow | T1wSE |
| Magic angle artifacts:<br>- DSIL<br>- deep digital flexor tendon<br>- collateral ligaments of the DIPJ<br>- CCL<br>- DDAL | All sequences |
| B1 inhomogeneity:<br>- podotrochlear region | T1wSE, PDwSE |
| Susceptibility artifact:<br>- distal border of the hoof capsule | FLASH, DESS, T1 MP-RAGE |
| Bending artifacts:<br>- Pastern | CISS, DESS |

**Table B.** Best sequences for selected anatomical structures

| Structures | Sequences | Comment |
|---|---|---|
| Tendons and ligaments | DESS, T1wSE better than CISS, T2wSE, PDw fs and non-fs | fibrillar structure in all including DSIL, ChSL, chondrocoronal ligament (CCL), DDAL and visible synovial fossae from the DIPJ in DSIL |
| Bones | T1wSE, PD2, DESS and FLASH | trabecular pattern |
| Articular cartilage | DESS, CISS, T1 MP-RAGE | Smooth and homogeneous delineation, good cartilage-to-fluid and cartilage-to-bone contrast |
| Synovia | T2wSE, PDwSE, DESS and CISS<br>T1 MP-RAGE and FLASH | Hyperintense to the cartilage<br>Hypointense to the cartilage |
| Vessels | DESS and FLASH | Hypointense wall contrasting to the surrounding structures and hyperintense lumen, easy to follow the course of the vessels thanks to a 3-dimensional reconstruction |
| Hoof wall | DESS<br>T1wSE | All layers were visible on DESS, including the stratum medium<br>Visualisation of the hyperintense individual lamellae on the transverse plane of T1wSE |

**Discussion / Conclusion:** 7T provides excellent delineation of the bones, tendons, ligaments, vessels, cartilage, synovial structures and layers of the hoof wall. 7 Tesla MRI is a promising method for future research on equine pathologies.

References

*a)* Keller, M. D., et al (2006). Magnetic resonance microscopy of the equine hoof wall: a study of resolution and potential. Equine VJ, 38(5), 461–466.

*b)* Juras, V., et al (2019). Magnetic Resonance Imaging of the Musculoskeletal System at 7T: Morphological Imaging and Beyond. TMRI, 28(3), 125–135.

*c)* Springer, E., et al. (2017). Comparison of Routine Knee Magnetic Resonance Imaging at 3T and 7T. Investigative radiology, 52(1), 42–54.

*d)* Theysohn, J. M., et al. (2013). MRI of the ankle joint in healthy non-athletes and in marathon runners: image quality issues at 7.0 T compared to 1.5 T. Skeletal radiology, 42(2), 261–267.

University of Bern | University of Zurich

vetsuisse-faculty

TRANSLATIONAL imaging center bern