IMAGING DIAGNOSIS - SPONTANEOUS DUODENOBILIARY REFLUX IN DOG

R.C. Purdoiu[1,2], S.M. Mârza[1], R. Lăcătuș[1], L. Bel[1], L. Carisch[2], P. Kircher[2]

1. Laboratory of Radiology and Medical imaging, Faculty of Veterinary Medicine, University of Agricultural Sciences and Veterinary Medicine Cluj Napoca, ROMANIA
2. Clinic for Diagnostic Imaging, Department of Diagnostics and Clinical Services, Vetsuisse Faculty, University of Zurich, Zurich, Switzerland

University of Zurich[UZH]
Division of Diagnostic imaging

Introduction

Reflux of barium sulfate into the biliary tree from the duodenum is a rare condition reported in human medicine, being associated with choledochoenterostomy, Oddi sphincter incompetence, or duodenal fistulae/ulcer.

Early studies mention barium sulfate as contrast medium for cholangiography after cholecystectomy, as an alternative to ionic, iodinated contrast agents that produces sphincter of Oddi spasm. In veterinary literature duodenobiliary reflux has been reported once in a dog secondary to duodenal resection and anastomosis due to duodenal ulceration and in a cat after linear foreign body obstruction of small intestine.

In our case, duodenobiliary reflux happened spontaneously during contrast evaluation of the GIT, as consequence of an abscessing pancreatitis.

Case presentation

A 3 years old, neutered male Yorkshire Terrier was referred to the radiology service of Faculty of Veterinary Medicine Cluj Napoca, for gastrointestinal tract evaluation due to inappetence, vomiting and lethargy. On physical examination the patient was assessed as overweighted, dehydrated with moderate abdominal pain on palpation. Result of blood analysis showed an inflammatory panel. After physical evaluation of the patient, an abdominal radiography was performed to exclude a possible foreign body (fig. 1), followed by a Barium study (fig. 2, fig. 3).

Fig 1 Lateral projection of the abdomen – no evidence of radiopaque foreign body

Medical imaging examination

Two hours after barium sulfate administration, the contrast was visible in the biliary tree. Orthogonal projection of the abdomen were acquired for 3 consecutive days. The biliary tree and the gall bladder were highlighted by the reflux of the duodenal content with barium sulfate (fig. 3, fig 4, fig. 5). Post contrast changes were evaluated using a Siemens Somatom Scope helical CT, the scan was performed 2 days after the initial barium intake. Multi-planar CT reconstruction evidentiate the reflux of the duodenal content into the biliary tree and show the severe inflammatory reaction of the pancreas (fig. 6). Abdominal ultrasound showed multiple focal hypo-echoic lesions in the pancreas, duodenal inflammation, adhesions and distended duodenal papilla (fig. 7, fig. 8, fig 9, fig. 10). These findings were confirmed by exploratory laparotomy.

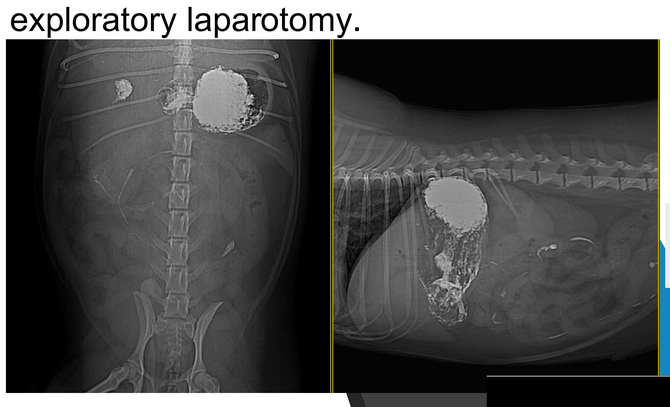

Fig 2 LL and Dv projection after barium sulfate ingestion

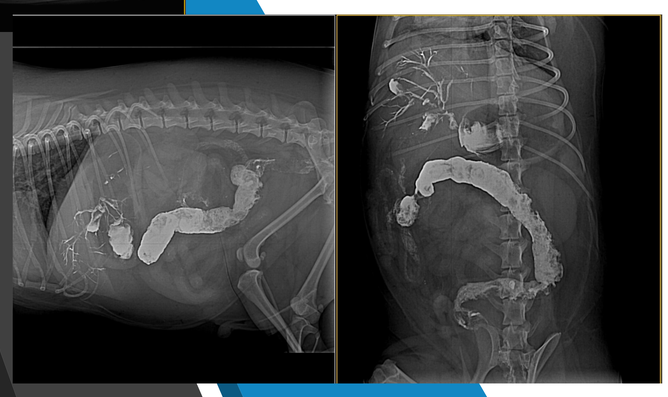

Fig 3 LL and Dv projection at 24 hours after barium sulfate ingestion – biliary tree visible

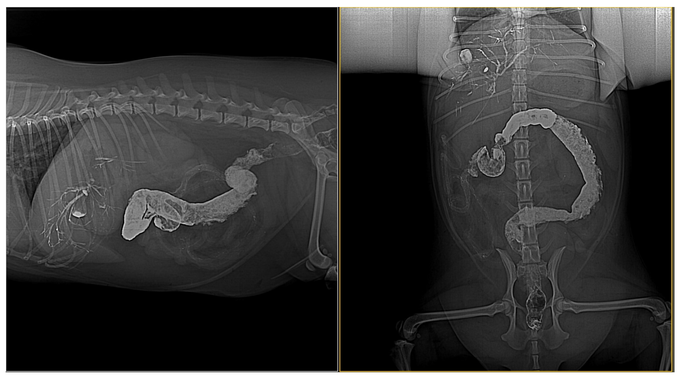

Fig 4 LL and Dv projection at 48 hours after barium sulfate ingestion

Fig 5 LL and Dv projection at 72 hours after barium sulfate ingestion

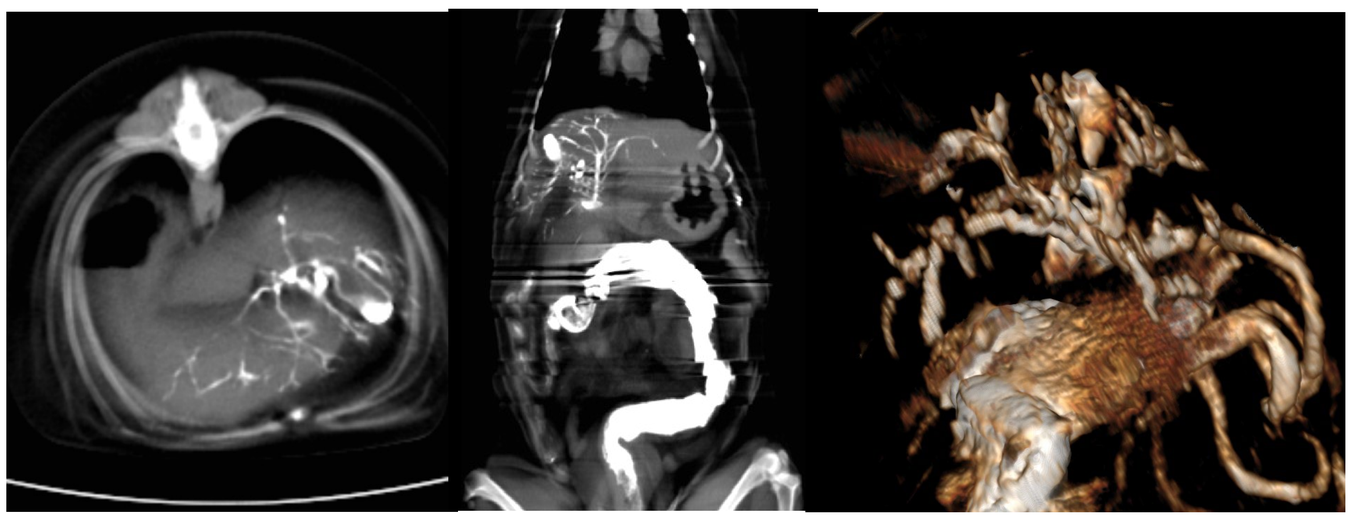

Fig 6 Axial, sagittal and volume rendering of the barium sulfate contrast enhanced biliary tree

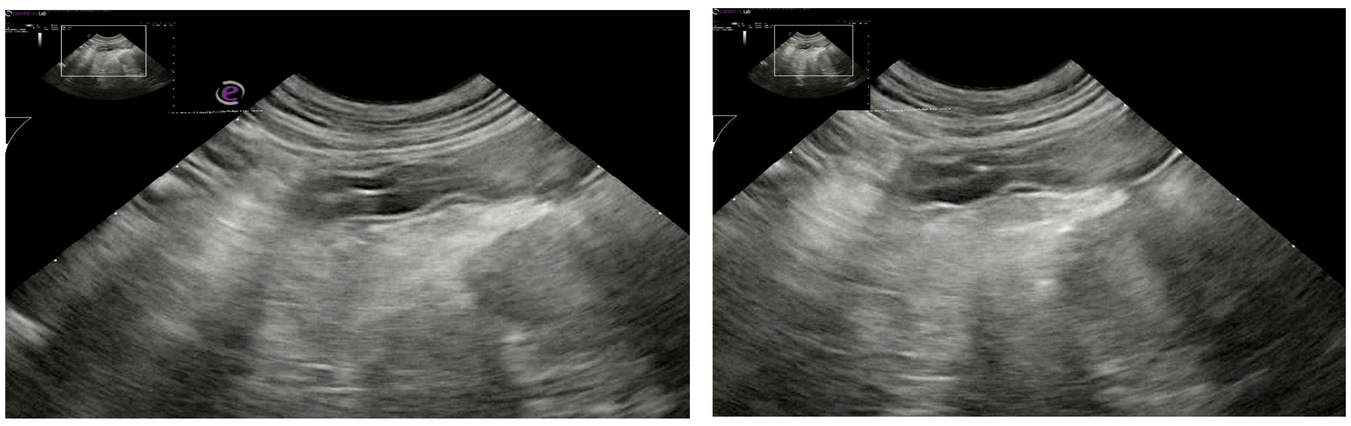

Fig 7 Duodenal inflammation and hypoechogenic pancreatic abscess

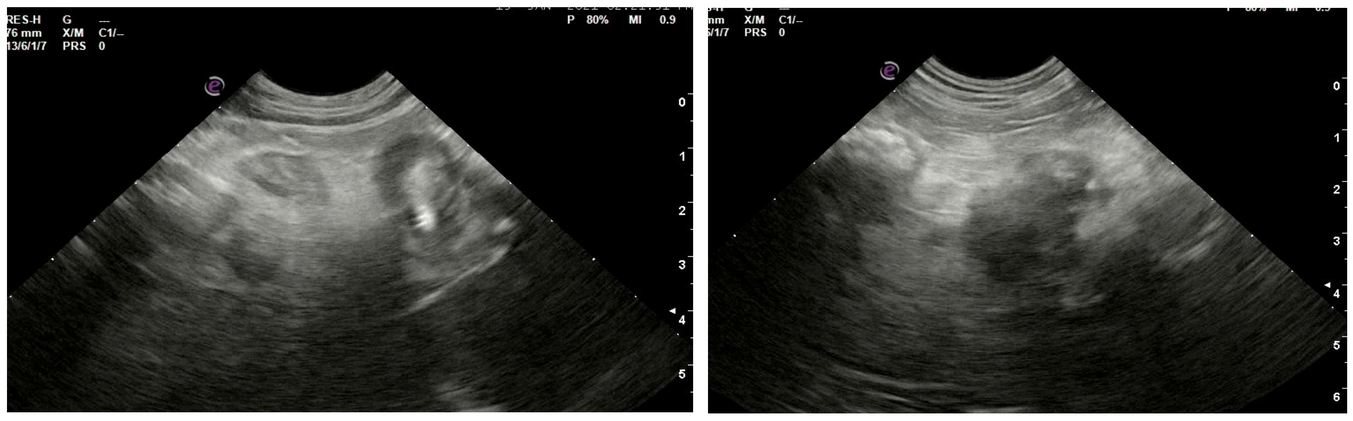

Fig 8 Multiple hypoechogenic pancreatic abscesses, duodenal and pancreatic adhesion

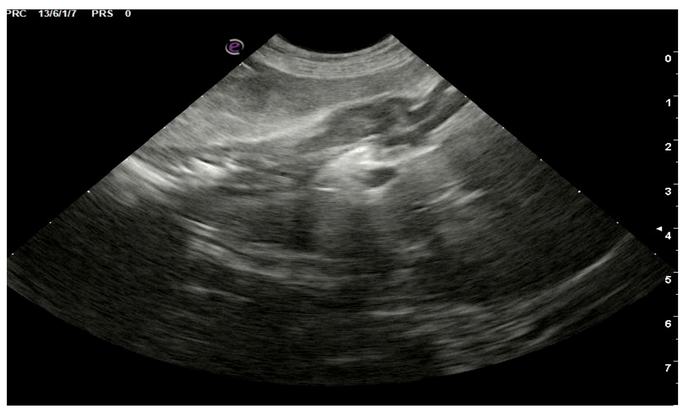

Fig 9 Sever duodenal inflammation, distension of duodenal papilla

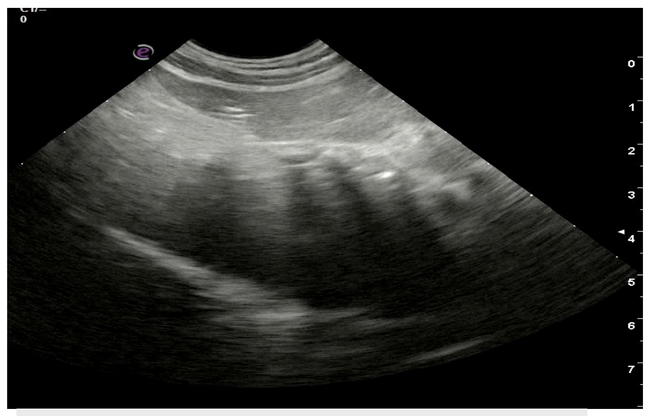

Fig 10 Acoustic shadowing produced by barium sulfate that reach the biliary tree

Discussion and conclusion

In this case, spontaneous duodenobilliary reflux (SDBR) may be a result of severe duodeno-pancreatic adhesions which in turn determine an abnormal response of cholecystokinin, influencing the opening of duodenal papilla.

In this case SDBR most probably represented a complication of severe pancreatitis. The shown reflux could provide an explanation for retrograde biliary infections.

References

1. Walsham A, Larsen J. Adverse effects of barium sulfate in the biliarytract. Diagn Interv Radiol 2008;14:94–96
2. Shaikh L, Sharma A, Secrst S. Imaging diagnostic – Duodenobiliary reflux of barium sulfate during esophago-gastrography is dog, Vet Radiol Ultrasound, 2015; 56(3):E36–E39
3. Dong M, Sonoda Y, Masahico K, Konomi H, Kobayashi K, Yamaguchi K, Tanaka M. Duodenum is important for the sphincter of Oddi motor response to cholecystokinin octapeptide in conscious dog. J Gastroenterol 2005; 40:389-395